

## TIPS AND TECHNIQUES

# The Deep Anchored Inner Thigh Lift

Guillermo Blugerman, MD; Diego Schavelzon, MD; Andres Galfrascoli, MD; Anastasia Chomyzsyn, MD; Andrea Markowsky, MD; Jorge D'Angelo, MD; Rodrigo Moreno, MD; Javier Soto, MD; Maria Siguen, MD

*The medial thigh area remains a troublesome region for body contouring in patients with lipodystrophy and/or skin flaccidity. Liposuction has proven effective in patients who have excess fat deposits but do not have a significant degree of skin laxity. The skin in this area of the body is often thin and inelastic, and in most circumstances where skin laxity is present, liposuction alone fails to remodel and tighten the inner thigh. Thus, it is necessary to combine liposuction with skin excision to achieve acceptable cosmetic results. The purpose of this article is to present the authors' technique of inner thigh lift using a novel dermo adipose flap design, which allows an effective anchoring of the inferior flap of the inner thigh to the adductor major tendon at the pubic bone insertion site. This novel approach creates a strong and stable anchoring site for the inferior inner thigh flap. In the authors' experience this technique has proved safe and effective, has a decreased morbidity, and achieves excellent cosmetic results.*

**A**dverse results associated with current inner thigh lifting procedures include pigmented or hypertrophic scars; flattening of the vulva as result of traction created by the lower flap on the vulvar tissues; caudal wound migration that cannot be hidden when the patient is wearing a swimsuit (Figure 1); and recurrence of inner thigh ptosis, which may require additional corrective surgery.<sup>1-3</sup>

The anatomic absence of a well-defined and strong superficial fascial structure to which to anchor the inferior flap in a stable position and the histologic characteristics of the skin of the inner thigh are two of the main reasons for poor results.

### Anatomy

The skin in the medial thigh has a minimal dermal component and an average thickness of 0.03 mm.

The subcutaneous tissue of this area is separated in 2 layers by a poorly defined superficial fascia.<sup>4</sup> The thickness and quality of the fascia varies considerably from patient to patient, and it can be difficult to identify this structure at the time of surgery when tumescent local anesthesia is used.

The adductor muscle tendon is a fibrous structure, a finger thick in diameter, that inserts on the ischiopubic portion of the pelvic bone (Figure 2). It is easily identifiable and there are no significant anatomic structures located behind the tendon. The superficial fascia (Colles' fascia) covers the tendon.

### Patient Selection

Correct patient selection and evaluation of their expectations are paramount. The strategy for treating these patients, who frequently require various body lifting and liposuction procedures, is planned at the initial visit. Evaluation of the degree of skin laxity and its quality, the overall extent of deformity of the inner thigh, and the extent of lipodystrophy present is crucial.<sup>5</sup>

An important aspect of the initial physical examination is the evaluation of the lower abdomen and mons pubis. In the presence of significant lower abdomen fat deposits, skin excess and a ptotic and enlarged fat pubic area, these parts should be treated before performing the inner thigh lift procedure.<sup>6</sup>

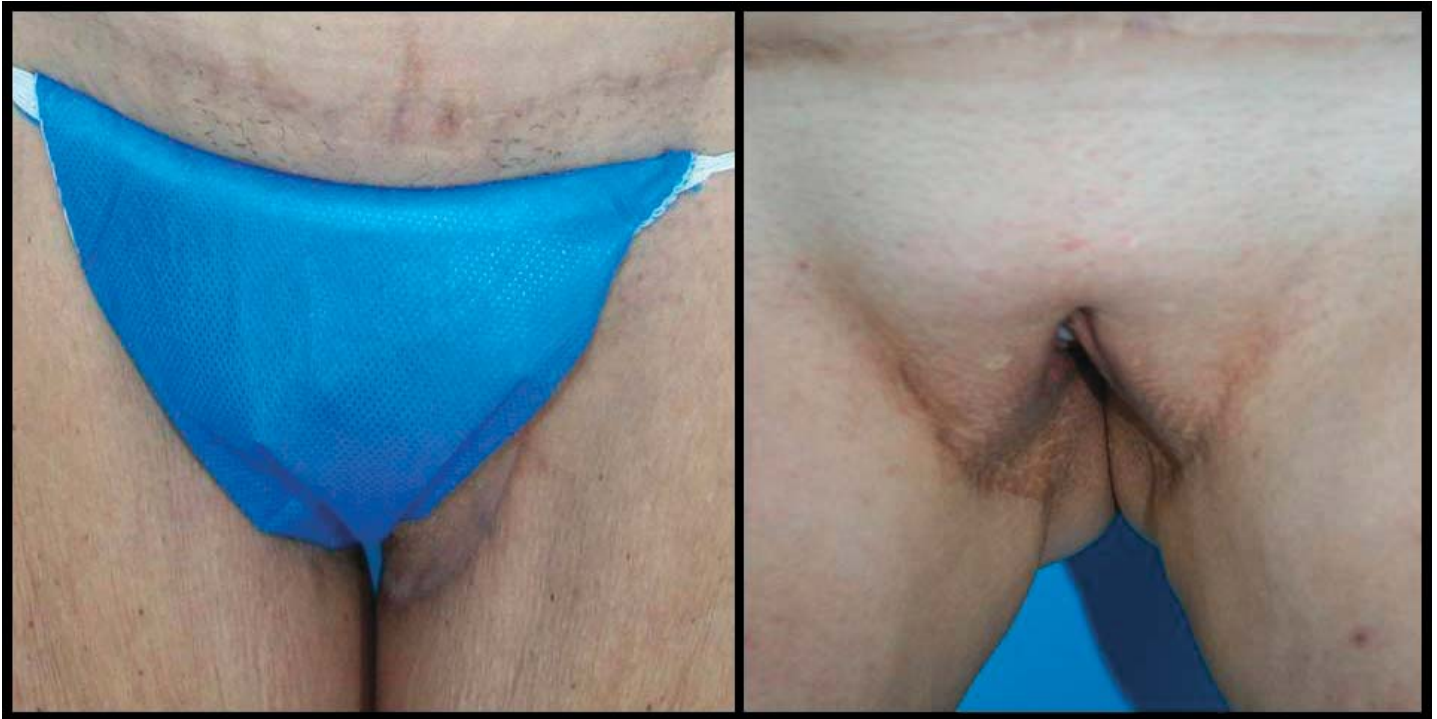In our experience a conservative approach to the inner thigh area using energy-assisted liposuction (ultrasound, laser, or radiofrequency) without skin resection has resulted in satisfactory improvement in 50% of our patients.

When liposuction fails to achieve adequate cosmetic results, however, inner thigh lift surgery is performed 3 to 6 months after the initial liposuction. The majority

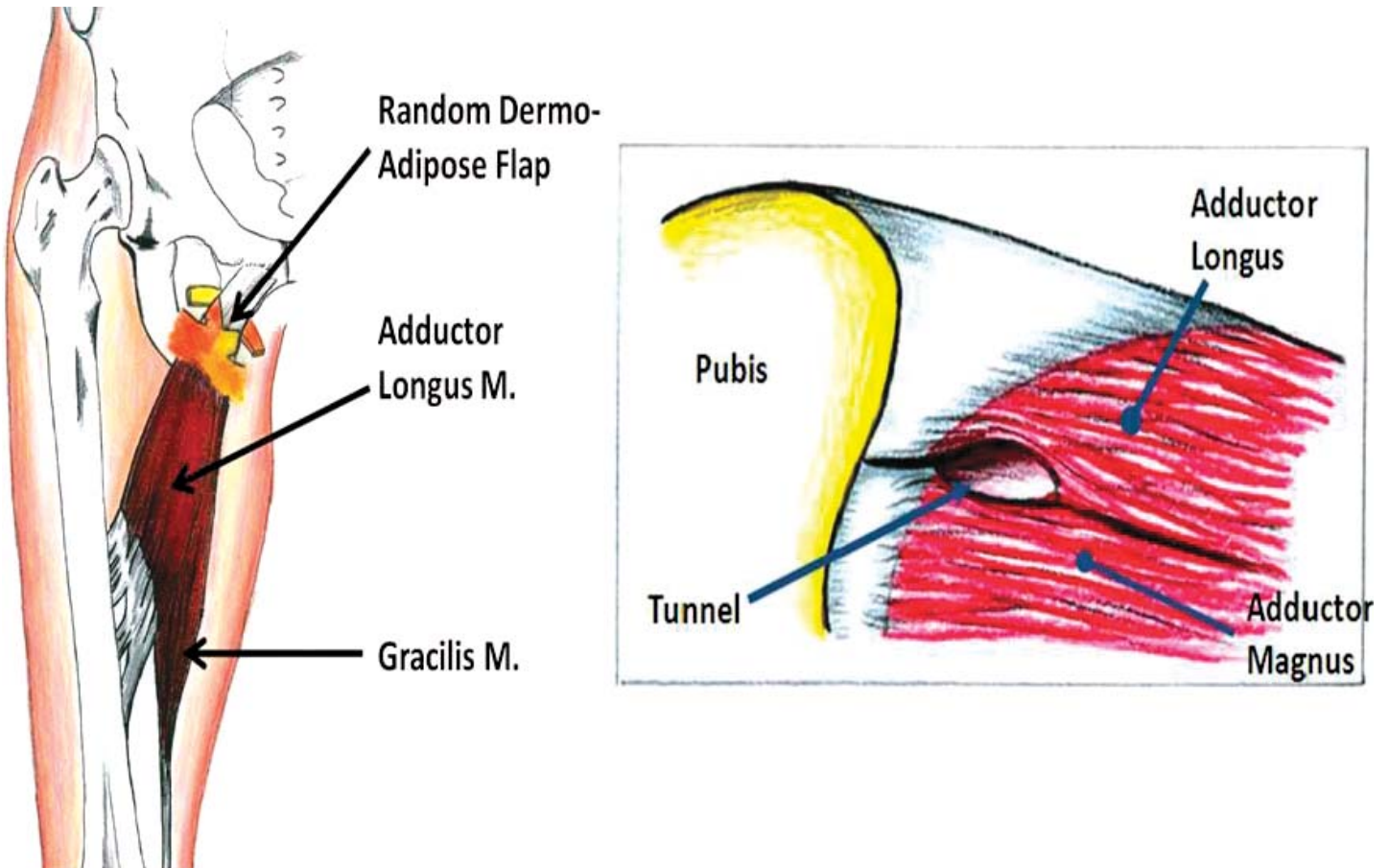
Received for publication February 18, 2011.

From the Centro B&S de Excelencia en Cirugía Plástica, Buenos Aires, Argentina. Dr Blugerman is also with the Universidad Nacional del Nordeste, Corrientes, Argentina.

Corresponding author: Guillermo Blugerman, MD, Centro B&S de Excelencia en Cirugía Plástica, Laprida 1579, Buenos Aires, CEKK1425, Argentina (e-mail: drblugerman@gmail.com).

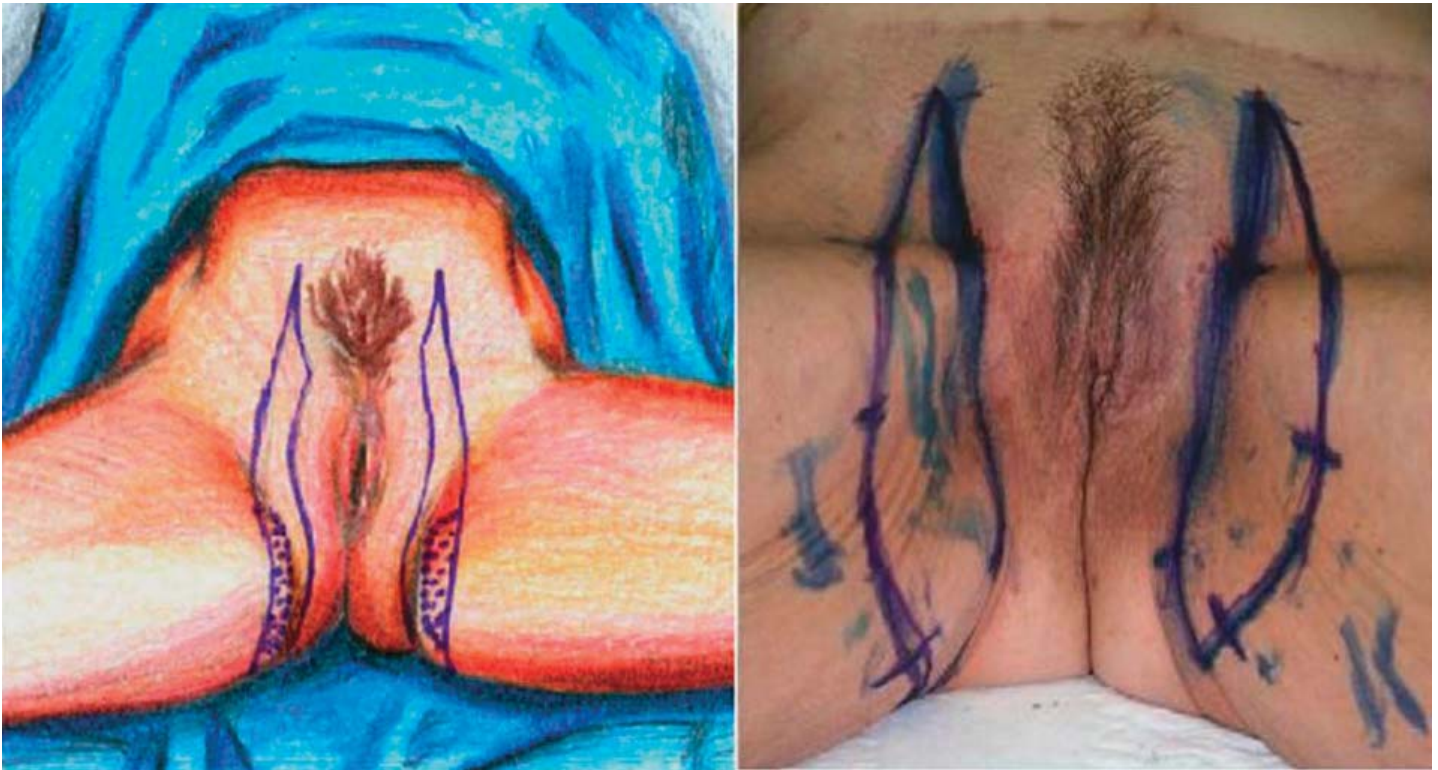


**Figure 1.** (left) Caudal scar migration that cannot be hidden when the patient wears a swimsuit. (right) Vaginal distortion because of skin over-resection.



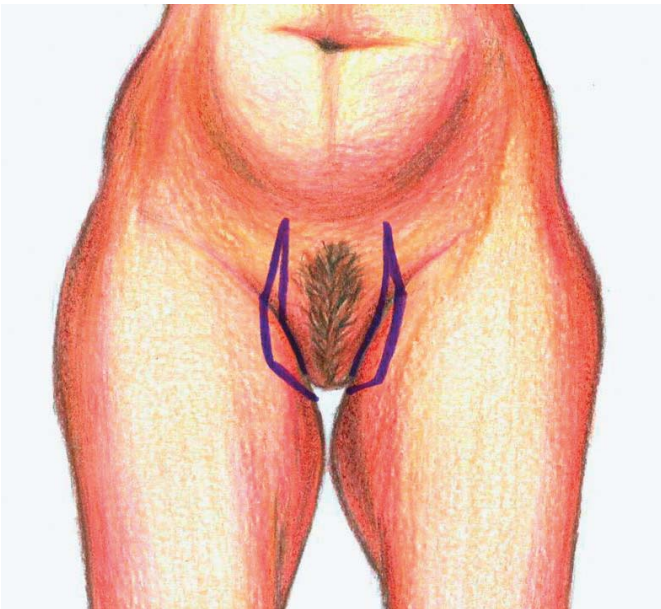
**Figure 2.** (left) Anatomy of the adductor muscles. Note the situation in which the dermal flap is fixed to the tendon. (right) The tunnel in the back of the tendon near the attachment to the pubic bone.





**Figure 3.** (left) Marking of the skin to be resected. (right) The dotted area corresponds to the dermal-adipose flap.

of our patients undergoing inner thigh lift are women between the ages of 35 and 75 years. We have found that in men the presence of hair in the inner thigh skin makes it difficult to create a dermal flap free of hair follicles.



**Figure 4.** Drawing the front view of the marking while the patient is standing.

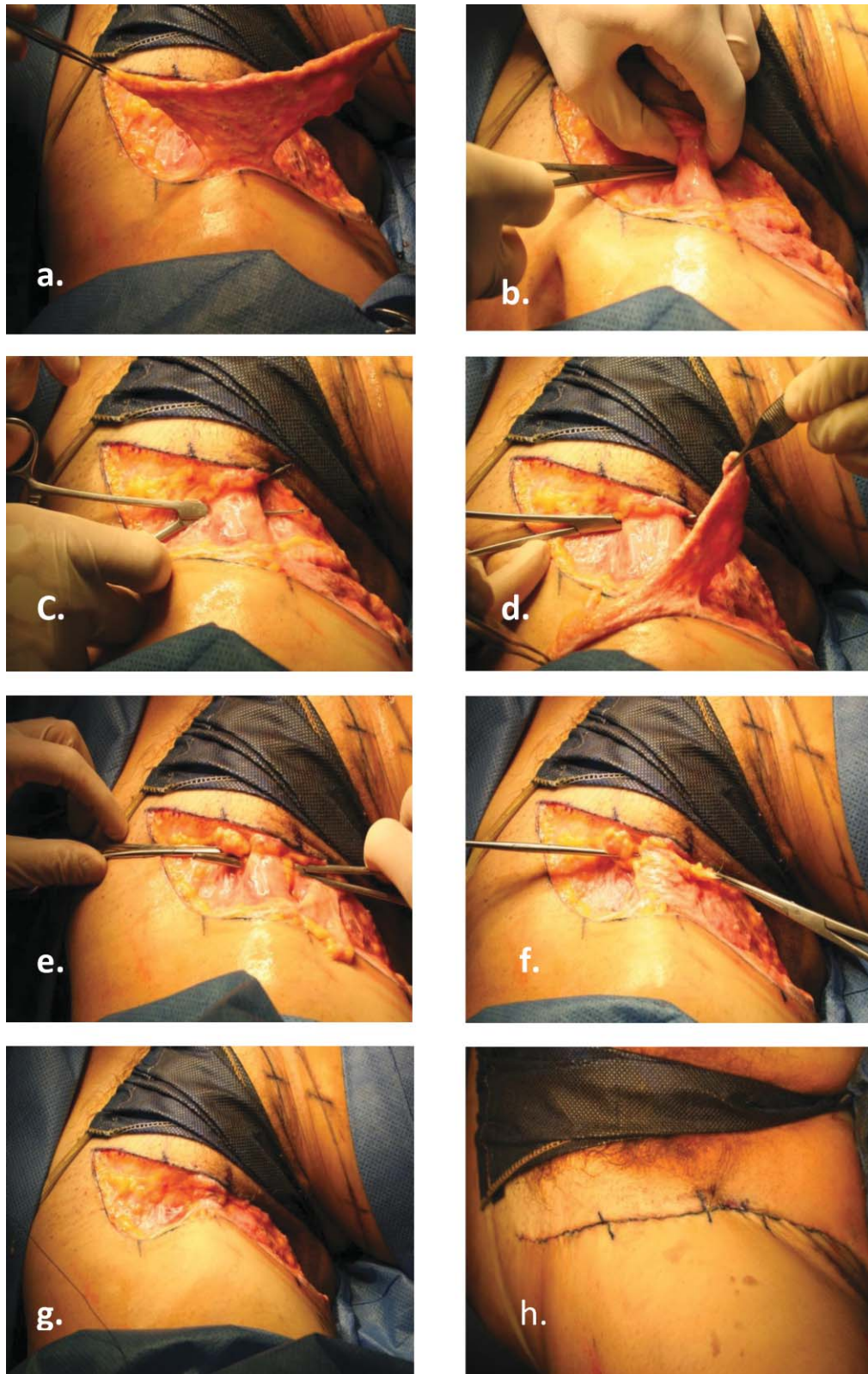
The Mathes<sup>7</sup> and Kenkel classification has been very useful in deciding what patients are good candidates for the authors' inner thigh lift procedure.

A standard comprehensive preoperative workup is performed in all patients. In patients at high risk for deep vein thrombosis, active preventive maneuvers are used at surgery, such as sequential compression and the use of compression socks. Contraceptive pills are discontinued to diminish the risk of thromboembolism.

### Surgical Technique

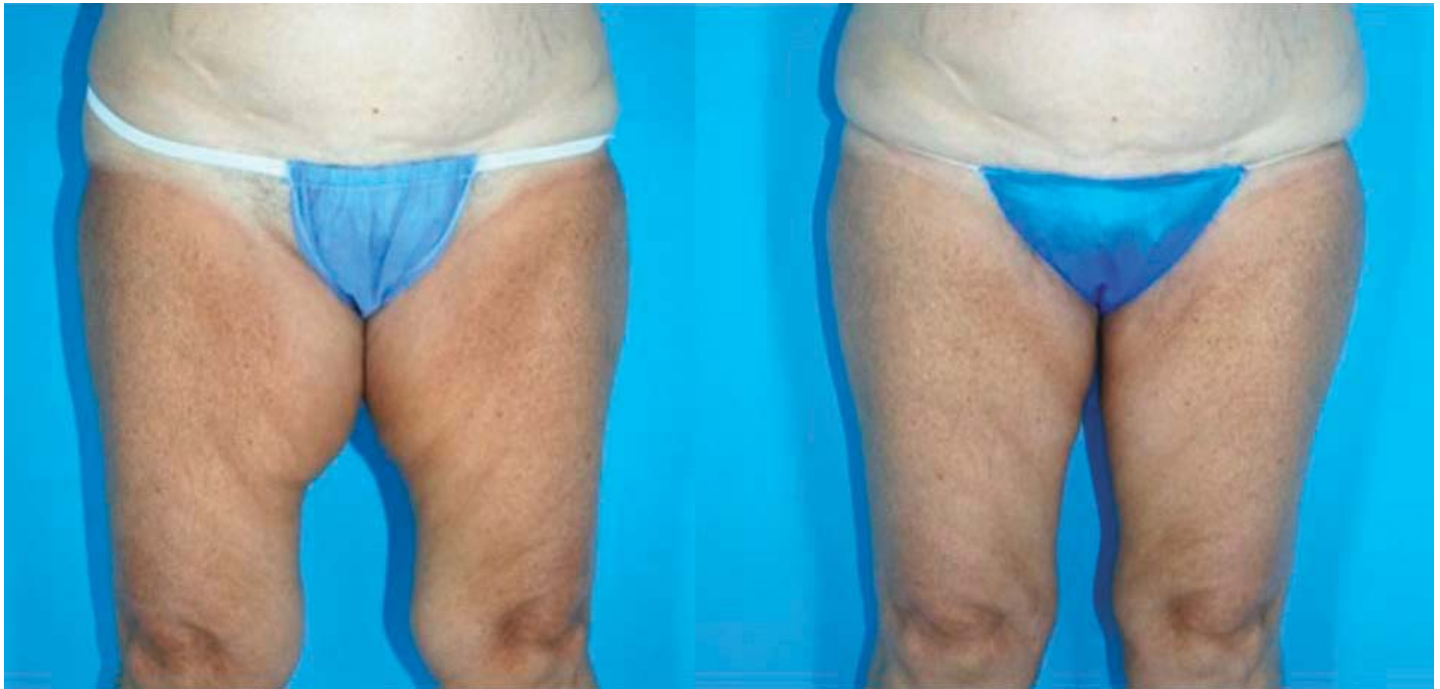A chlorhexidine soap shower is routinely performed just before the patient is moved to the operating room. Standard preoperative photographs are taken. Using a good-quality pen, the patient is marked in the standing position with the knees apart. Using the pinch test we determine the degree of redundant skin that needs to be removed and the amount of fat that will be suctioned by liposuction.<sup>8</sup> Marking the patient in a resting position may result in over-resection of the lower flap of the inner thigh. The marking of the outer border of the ellipsoid-shaped skin incision is then completed (Figure 3).

Our patients prefer scar placement on the sides of the pubis instead of the inguinal sulcus because it is



**Figure 5.** (a–b) Consecutive steps from the carving of dermal-adipose flap. (e–f) Tendinous tunnel creation. (g–h) Subsequent fixation.





**Figure 6.** (left) Preoperative and (right) postoperative photographs of medial thigh lift combining Radiofrequency Assisted Liposuction and dermal flap suspension to the adductor tendon.

easier to cover them with their underwear or beach garments. The medial incision of each side is marked vertically in one of the lateral borders of the mons pubis and is advanced vertically to the adductor tendon projection on the skin (Figure 4).

From the adductor tendon projection to the ischion projection the skin incision is placed in the sulcus that exists between the labia major lateral aspect and the inner thigh. We avoid extending the skin incision beyond the point of projection of the ischion at the buttock's fold. Care is taken to keep enough skin on the labia side to avoid distortion and preserve the normal anatomy of this area.

The extent of the ellipsoid skin excision ranges from 2 cm to 5 cm at the central area of the ellipse to be excised.

With the patient in the prone position we mark the dermal-adipose fixation flap. The dermal-adipose fixation flap is 1 cm wide and 8 to 10 cm long, with a central area 2 cm wide in the projection of the vector that we want to create during the flap elevation.

The patient is then placed in a frog-leg position with both feet in contact. A standard sterilization preparation is completed and local tumescent anesthesia is infiltrated. A 0.06% solution of lidocaine is infiltrated in the area to undergo liposuction, and 0.12% lidocaine is infiltrated on the area of skin resection.<sup>9</sup> After

the liposuction is completed using the Avelar approach, the epidermis is removed from the skin of the dermal-fat flap, preserving as much dermis as possible.<sup>10</sup> This step is carefully performed because this small flap is responsible for the anchoring of the lower inner thigh flap and holds the lower flap in place under tension after the surgery. The rest of the skin ellipsoid area is then removed.

During surgery deep dissection of the femoral triangle area is avoided to prevent potential serious bleeding and lymphatic trauma. At the dermal-fat flap, 2 strips 1 cm wide and 4 cm long are prepared. Using blunt dissection with a Halsted forceps, a tunnel is created under the adductor major tendon. Using the same forceps, the end of each dermo-adipose strip flap is grasped, and both ends are then passed under the tendon. The 2 flaps are then wrapped around the tendon. The flaps are fixed to the tendon and are sutured to each other and to the tendon with 2/0 permanent multifilament sutures. The excess of the flaps are resected.

The superficial fascia of Colles is identified. Using 2-0 poliglactin, anchoring sutures are placed to approximate the Colles' fascia with the subdermal layer of both superior and inferior skin flaps (Figure 5).

Superficial subcutaneous sutures are placed with 3-0 poliglecaprone sutures and sterile micropored tape

is placed on the skin to reduce the tension on the inner thigh lift suture line.

All patients receive single intravenous doses of antibiotics (cefazolin) during the procedure. Drains are not routinely placed. Compression garments are used for 3 weeks. Early ambulation starts the night of the surgery and is encouraged to reduce the risk of deep vein thrombosis. Most patients are discharged the day of the surgery.

### Discussion

Most of the current medial thigh lift techniques are based on Lockwood's<sup>11,12</sup> concept of supporting the thigh tissues with sutures.<sup>13</sup> The authors' technique introduces a more substantial approach to support the flap while reducing distortions of the vulva and mons pubis (Figure 6). This technique also avoids the T incision. The success of this procedure depends on patient selection, surgical planning, and patients' realistic expectations.

### References

1. Lewis JR Jr. Correction of ptosis of the thighs: the thigh lift. *Plast Reconstr Surg*. 1966;37:494–498.
2. Candiani P, Campiglio GL, Signorini M. Fasciofascial suspension technique in medial thigh lifts. *Aesthetic Plast Surg*. 1995;19:137–140.
3. Ersek RA, Salisbury AV. The saddle lift for tight thighs. *Aesthetic Plast Surg*. 1995;19:341–343.
4. Spirito D. Medial thigh lift and DE.C.LI.VE. *Aesthetic Plast Surg*. 1998;22:298–300.
5. Hurwitz DJ. Single-staged total body lift after massive weight loss. *Ann Plast Surg*. 2004;52:435–441.
6. Pitanguy I. Surgical reduction of the abdomen, thighs and buttocks. *Surg Clin North Am*. 1971;51:479–489.
7. Mathes DW, Kenkel JM. Current concepts in medial thighplasty. *Clin Plast Surg*. 2008;35:151–163.
8. Vilain R, Dardour JC. Aesthetic surgery of the medial thigh. *Ann Plast Surg*. 1986;17:176–183.
9. Le Louarn C, Pascal JF. The concentric medial thigh lift. *Aesthetic Plast Surg*. 2004;28:20–23.
10. Avelar JM. A new technique for abdominoplasty-closed vascular system of subdermal flap folded over itself combined with liposuction. *Revista Brasileira de Cirurgia*. 1999;88/89:3–20.
11. Lockwood TE. Fascial anchoring technique in medial thigh lifts. *Plast Reconstr Surg*. 1988;82:299–304.
12. Lockwood T. Lower body lift with superficial fascial system suspension. *Plast Reconstr Surg*. 1993;92:1112–1122 [discussion: 1123–1125].
13. Planas J. The “crural meloplasty” for lifting of the thighs. *Clin Plast Surg*. 1975;2:495–503.